

# The anatomy and physiology of normal and abnormal swallowing in oropharyngeal dysphagia

A. Sasegbon  | S. Hamdy

Gastrointestinal (GI) Sciences, Division of Diabetes, Endocrinology and Gastroenterology, School of Medical Sciences, University of Manchester, Salford Royal Hospital (part of the Manchester Academic Health Sciences Centre (MAHSC)), Salford, UK

## Correspondence

Prof. Shaheen Hamdy, Gastrointestinal (GI) Sciences, Division of Diabetes, Endocrinology and Gastroenterology, School of Medical Sciences, Faculty of Biology, Medicine and Health, University of Manchester, Salford Royal Hospital (part of the Manchester Academic Health Sciences Centre (MAHSC)), Salford, UK.  
Email: shaheen.hamdy@manchester.ac.uk

## Abstract

**Background:** Eating and drinking are enjoyable activities that positively impact on an individual's quality of life. The ability to swallow food and fluid is integral to the process of eating. Swallowing occupies a dual role being both part of the enjoyment of eating and being a critically important utilitarian activity to enable adequate nutrition and hydration. Any impairment to the process of swallowing can negatively affect a person's perception of their quality of life. The process of swallowing is highly complex and involves muscles in the mouth, pharynx, larynx, and esophagus. The oropharynx is the anatomical region encompassing the oral cavity and the pharynx. Food must be masticated, formed into a bolus and transported to the pharynx by the tongue whereas fluids are usually held within the mouth before being transported ab-orally. The bolus must then be transported through the pharynx to the esophagus without any matter entering the larynx. The muscles needed for all these steps are coordinated by swallowing centers within the brainstem which are supplied with sensory information by afferent nerve fibers from several cranial nerves. The swallowing centers also receive modulatory input from higher centers within the brain. Hence, a swallow has both voluntary and involuntary physiologic components and the term dysphagia is given to difficult swallowing while oropharyngeal dysphagia is difficult swallowing due to pathology within the oropharynx.

**Purpose:** Problems affecting any point along the complex swallowing pathway can result in dysphagia. This review focuses on the anatomy and physiology behind normal and abnormal oropharyngeal swallowing. It also details the common diseases and pathology causing oropharyngeal dysphagia.

## KEYWORDS

anatomy, dysphagia, oropharyngeal dysphagia, physiology

## 1 | INTRODUCTION

Swallowing is a universally critical process for enabling life, allowing food and fluid to be ingested safely and efficiently thereby maintaining normal physiological and biochemical functions. Furthermore, the enjoyment of eating and drinking plays an important part in an individual's perception of their quality of life.<sup>1,2</sup> Dysphagia is defined as difficult and/or disordered swallowing.<sup>3-5</sup> Various diseases can cause disruption to normal swallowing resulting in dysphagia. Dysphagia has the potential to cause malnutrition, dehydration and aspiration

pneumonia, which lead to significant mortality and morbidity.<sup>6</sup> The oropharynx is a compound term given to the anatomical region which includes the oral cavity and the pharynx. Hence, oropharyngeal dysphagia is essentially difficult swallowing due to pathology within the oropharynx.

This review will cover the anatomy and physiology of normal and abnormal swallowing as it pertains to oropharyngeal dysphagia (OPD). In addition this review will discuss diseases which cause OPD and highlight the pathophysiologic abnormalities that disrupt normal oropharyngeal swallowing.

## 2 | SWALLOWING

Classically the process of swallowing can be described as having three components. These are the oral, pharyngeal and esophageal phases of the swallow.<sup>7</sup> The oral component is voluntary and involves the lips, teeth, muscles of mastication and tongue and can be subdivided into two or more stages; the oral preparatory stage and the propulsive stage. With respect to fluids the oral preparatory phase is relatively simple requiring the initial containment and positioning of the ingested fluid before its subsequent aboral propulsion. With more solid foods requiring mastication, the oral preparatory phase is more extensive. This is because mastication requires food to be transported around the oral cavity to the teeth to be broken down with the aid of saliva. At the end of this process the consistency and texture of solid food has been made more liquid. It can then be positioned and swallowed as if it were a liquid to begin with. At this point the bolus is temporarily positioned within the anterior portion of the mouth. The posterior wall of this transient cavity is formed from the middle portion of the tongue and the soft palate. Depending on the type of normal swallow—tipper or dipper—the tip of the tongue is either above or below the bolus at this stage. The propulsive stage involves first positioning the bolus of fluid on the superior surface of the tongue. The tip of the tongue is then placed against the roof of the mouth and through anterior to posterior flexion, forces the bolus toward the pharynx.<sup>8</sup> The end product of this initial phase is the formation of a bolus. The latter two stages of swallowing are considered increasingly automatic and in some aspects more involuntary.<sup>7</sup> The involuntary stages of swallowing can be initiated by stimulating the superior laryngeal nerve (SLN), a branch of the vagus nerve.<sup>7,9</sup> Alternately, the process of swallowing has been described in terms of two phases: oropharyngeal and esophageal. The reason for this change in classification is because the pharyngeal phase of swallowing relies on some muscles of the oral cavity such as the supra-hyoid muscles and the tongue.<sup>7</sup> Therefore swallowing can be thought of as comprising two phases: the first of which has an initial voluntary component, the second (pharyngeal) component being more reflexive.

### 2.1 | Anatomy and physiology

The first phase of swallowing involves mastication and the formation of a bolus. This process is aided by saliva. Saliva has many beneficial physiological properties. In the context of swallowing, it helps soften and dissolve food thereby easing mastication. It also serves to lubricate and facilitate the passage of the subsequently formed bolus into the pharynx.<sup>10,11</sup> The physical act of crushing and altering the consistency of ingested food is made possible by the teeth jaws and the muscles attached to the mandible. An adult human has 32 permanent teeth.<sup>12</sup> Their primary function is to slice, grasp and grind ingested food with the aid of saliva. They also contribute to the articulation of words when speaking.<sup>12</sup> Teeth are characterised as either: incisors, canines, premolars or molars. Incisors help slice food, while the other categories help grasp and grind food. All teeth are innervated by the maxillary and

#### Key Points

- Problems affecting any point along the complex swallowing pathway can result in dysphagia.
- This review focuses on the anatomy and physiology behind normal and abnormal oropharyngeal swallowing. It also details the common diseases and pathology causing oropharyngeal dysphagia.

mandibular branches of the trigeminal nerve.<sup>12</sup> The muscles of mastication include the: temporal, masseter, lateral, and medial pterygoids.<sup>12</sup> All muscles are innervated by the mandibular branch of the trigeminal nerve.<sup>12</sup> The medial pterygoid, temporal, and masseter act to close the jaw.<sup>12</sup> The lateral pterygoids act to depress the chin when they contract bilaterally but unilaterally act to move the jaw toward the contralateral side.<sup>12</sup> The mandible interacts with the temporal bone at the temporomandibular joint.<sup>12</sup> During this process the lips are kept closed by the actions of the orbicularis oris, the buccinator, the risorius and the depressors and elevators of the lips.<sup>12</sup> These muscles are innervated by the facial nerve (CN VII).<sup>12</sup> After mastication the tip of the tongue makes contact with the anterior aspect of the hard palate. Muscular contraction then causes increasing amounts of the tongue to make contact with the palate moving from the anterior to posterior aspect of the pharynx.<sup>8</sup> This causes the food bolus to be pressed against the hard palate and pumped backwards toward the pharynx.<sup>8</sup> This movement is possible because the tongue is a complex and highly maneuverable muscular organ composed of both intrinsic and extrinsic muscles.<sup>12</sup> Intrinsic muscles attach to other muscles in the tongue and include the superior and inferior longitudinal, vertical and transverse muscles.<sup>12</sup> The extrinsic muscles attach to structures such as the hyoid bone, the styloid process, and aponeuroses and include the: hyoglossus, styloglossus, genioglossus, and palatoglossus.<sup>12</sup> The tongue is a muscular hydrostat.<sup>13</sup> Due to the high water content of muscle it is essentially incompressible. This means each contraction from each of its component muscles results in an equal degree of contralateral extension so as to keep the tongue's overall volume uniform. This results in increased maneuverability.<sup>13</sup> The soft palate plays an important role in the oral phase of swallowing. It is composed of five muscles. These are the: tensor veli palatine; palatoglossus; palatopharyngeus; levator veli palatine; and musculus uvulae<sup>12</sup> (Table 1). During the process of swallowing the soft palate elevates and makes contact with the nasopharynx, sealing it and preventing the reflux of food or fluids into the nasal cavity.<sup>8</sup>

The pharynx is a muscular chamber with two important but separate functions, namely respiration and the ingestion of food and liquids. During the process of swallowing the pharynx must reconfigure itself from an organ of respiration to one of food transport.<sup>1,4</sup> The first muscle involved in the more “automatic” phase of oropharyngeal swallowing is the mylohyoid.<sup>7</sup> After its activation a sequence of muscles contract and relax with the purpose of forcing the bolus to the upper esophageal sphincter (UES).<sup>1,4,7</sup> These muscles are: anterior digastric, geniohyoid, stylohyoid, styloglossus, posterior portion of the tongue,

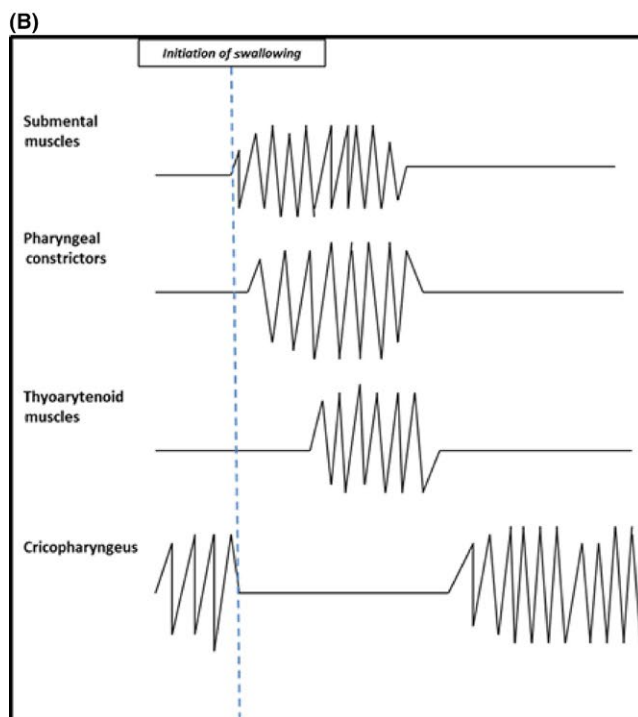
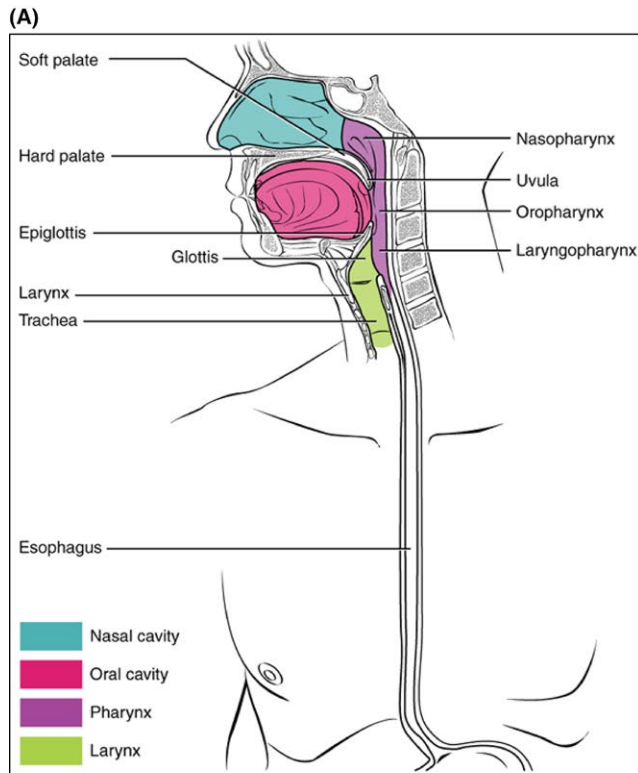
**TABLE 1** Oropharyngeal musculature and innervation

Phases of swallowing	Muscle groups	Individual muscles	Innervation		
Oral phase	Lips and cheeks	Orbicularis oris	Facial Nerve (CN VII)		
		Buccinator			
		Risorius			
		Lip elevators			
		Lip depressors			
	Tongue	Superior and inferior longitudinal muscles	Facial (CN VII) and Glossopharyngeal (CN IX) nerves provide taste fibers to the tongue. The Hypoglossal (CN XII) nerve is responsible for muscular contraction.		
		Transverse			
		Vertical			
		Genioglossus			
		Hyoglossus			
		Styloglossus			
		Palatoglossus			
		Mandibular muscles		Temporal	Facial nerve (CN VII)
				Masseter	
Lateral pterigoids					
Medial pterigoids					
Pharyngeal phase	Soft palate	Tensor veli palatine	Mandibular branch of trigeminal nerve (CN V <sub>3</sub> )		
		Palatoglossus	Pharyngeal branch of vagus nerve (CN X)		
		Palatopharyngeus			
		Levator veli palatine			
		Musculus uvulae			
	Pharyngeal musculature	Anterior digastric	Inferior alveolar nerve		
		Geniohyoid,	Hypoglossal nerve (CN XII)		
		Stylohyoid,	Facial nerve (CN VII)		
		Styloglossus,	Hypoglossal nerve (CN XII)		
		Superior, middle and inferior constrictors	Vagus nerve (CN X)		
		Palatopharyngeus			
		Palatoglossus	Hypoglossal Nerve (CN XII)		
	Upper esophageal sphincter	Cricopharyngeus	Vagus nerve (CN X)		

Adapted from: Moore K, Dalley A. Clinically Oriented Anatomy. 5 ed.<sup>12</sup>

superior/middle/inferior constrictors, palatoglossus, and palatopharyngeus.<sup>7</sup> This sequence of muscle contractions has been described in literature as the initiating swallowing complex. The process of sequential muscular activity continues with the contraction of the middle and inferior pharyngeal constrictors respectively. In the non-swallowing state, the UES is kept closed by the tonic constriction of the cricopharyngeus.<sup>7</sup> However, once the process of swallowing has begun this relaxes until the bolus has reached the esophagus.<sup>7</sup> The relaxation and subsequent opening of the UES occurs in two stages. When the pharyngeal phase of swallowing is initiated there is a temporary inhibition of signals from the vagus nerve to the muscular complex which forms the UES. This results in a reduction in sphincteric tone.<sup>14-16</sup> Subsequent to this initial relaxation, vagally mediated contraction of the suprahyoid muscles causes further reduction in sphincteric tone and opening of the UES. This serves to further facilitate bolus passage. As the bolus

transits through the open UES its transient reduction in tone ceases and its high resting tone is restored.<sup>14-16</sup> The diagram below is an illustrative adaptation of an electromyogram detailing muscle activity in the submental; superior pharyngeal constrictor, thyroarytenoid, and cricopharyngeus muscles over the course of a swallow (Figure 1a,b).<sup>17</sup> As can be seen there is initial contraction of submental muscles followed swiftly by contraction of the superior pharyngeal constrictors. There is subsequent thyroarytenoid contraction illustrating the conversion of the pharynx to an organ of muscular transport. During this time it can be seen that the cricopharyngeus is relaxed. Tonic contraction only resumes in the intervals between swallows. The UES can be influenced in health (and in OPD) by a number of different factors. In an early study examining 10 healthy individuals using videofluoroscopy (VFS) and manometry, the mean flow rate of matter through the UES was found to be influenced by the volume and viscosity of the



**FIGURE 1** Anatomy of the mouth pharynx and esophagus. Obtained from OpenStax CNX [Internet]. Cnx.org. 2017 [cited 3 April 2017]. Available from: <https://cnx.org/contents/FPtK1z mh@8.81:HZpu8mRK@5/The-Mouth-Pharynx-and-Esophagus> (A); Illustration depicting Electromyogram (EMG) recordings from: submental pharyngeal, thyroarytenoid, and cricopharyngeus muscles during a swallow.<sup>17</sup> Adapted from: Perlman A. Electromyography in oral and pharyngeal motor disorders *GI Motility online*. 2006 (B)

bolus being swallowed.<sup>18</sup> It was found that barium prepared to thin liquid viscosity flowed faster through the UES compared to barium prepared to paste viscosity.<sup>18</sup> The UES was noted to open for longer with increasing barium viscosity. Another study by Bisch et al. confirmed an increased duration of UES opening with boluses of thicker viscosity in individuals with OPD due to strokes and a variety of neurological diseases.<sup>19</sup> However, these early findings have been challenged by the results of other more recent study which found no difference in the duration of UES opening with increasing bolus viscosity nor an inverse relationship between viscosity and the duration of UES opening.<sup>20</sup>

After the passage of the bolus through the UES the esophageal phase begins, resulting in the bolus being transported by peristalsis to the stomach. As this occurs, the laryngeal vestibule (LV) must remain closed to prevent aspiration of food or fluids.<sup>4,5,21,22</sup> From beginning to end, the oropharyngeal phase of swallowing can last between 0.6 and 1 second.<sup>5,7,22</sup>

## 2.2 | Neuroanatomy

The neuroanatomy of the oropharyngeal phase of swallowing can be subdivided into three categories for ease of understanding. These are: afferent neurons, interneurons, and efferent neurons. However, it must be noted that while a cranial nerve may have a predominantly afferent or efferent role, most have both sensory and motor components.

### 2.2.1 | Afferent neurons

Neuroanatomically, the oropharyngeal phase of swallowing is highly complex and less “automatic” than the esophageal phase of swallowing.<sup>7</sup> This is due to the high degree of conscious control of the initial oral phase of swallowing. There is integration and overlap of the oral neuronal pathways with the subsequent pharyngeal pathway. Cranial nerve (CN) V (trigeminal) provides sensory information from the mouth while CN VII (facial), IX (glossopharyngeal), and X (vagus) provide pharyngeal sensory information.<sup>12,23</sup> The SLN is a branch of the vagus nerve (CN X) formed from the inferior ganglion of CN X (vagus) at the level of the second cervical vertebrae. It splits into an external and an internal branch at the level of the third cervical vertebrae.<sup>12</sup> The external laryngeal nerve is a predominantly motor nerve and supplies the cricothyroid muscle while the internal laryngeal nerve is predominantly sensory and supplies the pharynx and superior region of the larynx.<sup>12,24</sup> CN VII (facial) and IX (glossopharyngeal) also have additional special sensory roles in providing taste fibers to the tongue. The facial nerve supplies fibers to the anterior two-thirds of the tongue and the glossopharyngeal nerve to the posterior third.<sup>12</sup> These afferent neurons supply information to the nucleus tractus solitarius (NTS), a sensory relay within the medulla.<sup>7</sup> Non-invasive studies using electrodes to stimulate specific regions within the brain in an attempt to initiate the rhythmic neuronal activity characteristic of swallowing, have identified the NTS as the region where swallowing can be induced.<sup>25,26</sup> The NTS was further confirmed to initiate neuronal swallowing activity within the central nervous system (CNS)

through animal studies which injected excitatory amino acids (EAAs) into defined regions of the brain to stimulate rhythmic neuronal firing.<sup>27,28</sup> Lesions of the NTS prevent afferent impulses to the SLN from initiating swallowing.<sup>7</sup> The NTS communicates with swallowing neurons in the region of the nucleus ambiguus.<sup>29</sup> These neurons then drive the motor neurons and the subsequent orderly pattern of muscle contraction needed for oropharyngeal swallowing to occur. This network of connecting neurons within the medulla oblongata is called the central pattern generator (CPG).<sup>5,7</sup> Two CPGs exist, one on either side of the medulla oblongata. They operate in tight synchrony and can be considered a single functional unit. Each half of the CPG is supplied by afferent nerve fibers from the ipsilateral side of the mouth and pharynx, for example the ipsilateral branches of the SLN 14.<sup>7</sup>

### 2.2.2 | Interneurons

Synchronicity is achieved between the two halves of the CPG through communication via swallowing interneurons. The CPG is the principal orchestrator of swallowing but can be modified by inputs from cortical and subcortical areas of the brain.<sup>7,30</sup>

### 2.2.3 | Efferent neurons

The motor neurons identified as coordinating oropharyngeal swallowing include cranial nerves V (trigeminal), VII (facial), IX (glossopharyngeal), X (vagus), XI (accessory) and XII (hypoglossal).<sup>5,7</sup> CN V (trigeminal) and CN XII (hypoglossal) are predominantly involved in the voluntary oral component of oropharyngeal swallowing as between them they innervate most muscles in the oral cavity. CN V (trigeminal) innervates the muscles of mastication which help reconstitute ingested food so it is able to be formed into a bolus. CN XII (hypoglossal) primarily innervates the tongue.<sup>12</sup> Additionally CN XII (hypoglossal) assists CN VII (facial) in sealing an individual's lips and by so doing preventing spillage of fluids or food.<sup>8,12</sup> The only muscle not to be supplied by the pharyngeal plexus is the tensor veli palatine. It is supplied by a branch of the mandibular branch of CN V (trigeminal).<sup>12</sup>

### 2.2.4 | Innervation of the salivary glands

There are three main pairs of salivary glands. These are the parotid, submandibular and sublingual glands.<sup>31</sup> The salivary glands receive parasympathetic and sympathetic innervation. Parasympathetic neuronal impulses cause an increase in saliva secretion while sympathetic impulses cause the secretion of more viscous saliva.<sup>10</sup> The parotid salivary glands are supplied by parasympathetic nerves from the glossopharyngeal nerve while the submandibular and sublingual glands are parasympathetically innervated by the trigeminal nerve. Sympathetic fibers from the superior cervical ganglion innervate all three pairs of salivary glands.<sup>31</sup>

### 2.2.5 | Lesions to neurons

Lesions to individual cranial nerves involved in swallowing cause different effects depending on the function of the nerve. Animal

studies have demonstrated that lesions to the motor nuclei of CN V (trigeminal) do not affect the involuntary phase of swallowing.<sup>8</sup> However, lesions to CN V (trigeminal) can severely affect mastication and by so doing affect the preparation of a food bolus for swallowing. CN VII (facial) innervates muscles of the face.<sup>12</sup> Lesions to this can cause inadequate sealing of the lips and spillage from the mouth.<sup>32</sup> It also affects swallowing through impairment of the posterior belly of the digastric muscle which helps elevate the hyoid bone during swallowing.<sup>12</sup> CN IX (glossopharyngeal) innervates muscles of the pharynx in combination with CN X (vagus) through the pharyngeal plexus.<sup>12</sup> Damage can affect bolus transit through the oropharynx. Along with CN X (vagus), CN IX (glossopharyngeal) provides sensory innervation to the pharynx.<sup>12</sup> Lesions to CN X (vagus) can result in motor and sensory effects affecting swallowing.<sup>32</sup> Damage to motor fibers negatively affects pharyngeal muscle contraction. In addition the SLN serves to initiate the process of pharyngeal swallowing.<sup>7</sup> Damage to sensory fibers can affect the initiation of the pharyngeal phase of swallowing.<sup>7</sup> CN XI (hypoglossal) supplies the muscles of the tongue.<sup>12</sup> Damage has a significant negative impact on tongue movements thereby affecting bolus positioning and propulsion.<sup>32</sup>

## 3 | VARIATIONS TO THE NORMAL SWALLOW

The process by which a bolus is transported toward the pharynx in health can vary. Two variants of normal swallowing exist. These are namely "tipper swallowing" and "dipper" swallowing.<sup>33</sup> Tipper swallowing is the most common form of swallowing in healthy individuals with one study showing tipper swallows in 72% of its 258 participants.<sup>33</sup> It involves the ingested food or fluid being held on the superior surface of the tongue with the tip of the tongue in contact with the maxillary incisors or held against the beginning of the hard palate.<sup>33</sup> When swallowing occurs the tongue is pressed against the palate and contracts forcing the bolus over its surface in an anterior to posterior direction toward the pharynx.<sup>33</sup> The dipper swallow differs from the tipper swallow as at the beginning of the swallowing process the bolus is largely within the anterior sublingual meatus, with the tip of the tongue above it. When swallowing occurs the tip of the tongue dips below the bolus and lifts it onto the tongue's anterior surface. From this point the dipper swallow proceeds in an identical way to the tipper swallow.<sup>33</sup> The dipper variant of swallowing has been observed to occur in a significantly greater proportion of patients over 60 years old.<sup>33</sup>

## 4 | FUNCTIONAL IMPAIRMENT ALONG THE SWALLOWING PATHWAY

For ease of understanding and categorization, the functional problems affecting the oropharyngeal phase of swallowing can be split into oral problems and pharyngeal problems.

## 4.1 | Oral impairment

During the oral phase of swallowing food is contained in the mouth before being prepared into a form that can be easily swallowed. Depending on whether fluids or foods are ingested, this is either a two or four step process. The oral phase of fluid ingestion is relatively simple and occurs in two steps. When fluids are ingested, the fluids are held in the anterior aspect of the mouth before being propelled toward the pharynx. The ingestion of food is more complex and can be viewed as a four step process. This requires closure of the mouth and retention of food; mastication; the formation of a bolus by muscles of the oral cavity using saliva and the positioning of the bolus at the faecal pillars.<sup>8</sup> Sensory information from the oral cavity provides the information needed for bolus preparation to occur.<sup>7</sup> Weakness of the tongue and other muscles of the oral cavity or loss of oral sensation can impair either or all of these oral preparatory and propulsive stages. This can result in (premature) spillage of food from the mouth, improper bolus formation or inadequate bolus positioning.<sup>8,32</sup>

## 4.2 | Pharyngeal impairment

As mentioned above, the pharynx is a muscular organ used for both breathing and the transport of ingested matter. Due to its dual use it must be safely configured from an organ of respiration to one of transport.

### 4.2.1 | Transport problems

The tongue provides the initial push forcing the bolus into the pharynx.<sup>34</sup> At this point, sensory information is conveyed to the CPG via the SLN to initiate the pharyngeal swallow.<sup>29</sup> Failure of sensory information to reach the CPG can impair this phase of swallowing. Weakness or incoordination of the muscles of the pharynx can result in slowed bolus transit across the oropharynx or food residue remaining in the oropharynx.<sup>32</sup> Studies have shown that both of these factors increase the risk of aspiration.<sup>35-37</sup> Pharyngeal muscle weakness can also cause backflow of food and fluids into the nasopharynx due to inadequate muscular sealing.<sup>32</sup>

### 4.2.2 | Obstruction

The bolus must now pass through the UES to transition from the pharynx to the esophagus.<sup>38</sup> As previously explained this requires: vagally mediated relaxation of the UES; contraction of suprahyoid muscles to facilitate opening of the sphincter and finally propulsion from pharyngeal muscles.<sup>8,32</sup> Problems with any of these steps can cause obstruction. Lesions to CN X (vagus) can cause hypertonicity of the UES. Increased UES tone can also be caused by scarring or fibrosis.<sup>32</sup> Muscle weakness can cause poor UES opening or inadequate pharyngeal propulsion of the bolus.<sup>14,39</sup>

### 4.2.3 | Failure of airway protection

Muscle weakness and incoordination can often prevent the pharynx fully transitioning from an organ of respiration to one of transport.

This causes failure of a normally prompt and complete closure of the LV and subsequent aspiration.<sup>32</sup>

## 4.2.4 | Co-ordination of breathing and swallowing

As previously described, the pharynx is an organ with two separate functions. Greater understanding of the complex interplay between the neurological cascades required for swallowing and respiration has developed over several decades involving both animal and human studies. An early animal study showed that during the process of swallowing there is inhibition of the activity of inspiratory neurons.<sup>40</sup> A later study by Sumi et al. confirmed the earlier findings of inspiratory inhibition with swallowing initiation.<sup>41</sup> However, this study also went further to demonstrate that there was a complex overlap between the swallowing and respiratory neuronal systems.<sup>41</sup> For example, in normal circumstances, swallowing usually inhibits inspiration but when hypoxia and hypercarbia are present swallowing ceases to inhibit inspiration as breathing is prioritized. These findings have been confirmed in more recent research.<sup>42</sup>

This co-ordination between swallowing and respiration has been observed to break down in some circumstances. Chronic obstructive pulmonary disease (COPD) is a respiratory disease characterized by lung damage and chronic changes to pulmonary airflow and gas transfer. A study by Cvejic et al. showed patients with exacerbations of COPD have a significant delay in the swallowing reflex.<sup>43</sup> This phenomenon is thought to explain the finding of a greater frequency of high penetration-aspiration scores in patients with COPD compared to those without disease.

## 5 | EPIDEMIOLOGY

Unfortunately as OPD is not a distinct disease, but rather a symptom of many disease processes, information available regarding epidemiology is inconsistent.

Due to the importance of OPD and subsequent aspiration in patients following strokes, the greatest body of epidemiological work has been done in this field. Numerous studies have established that OPD is a very common complication following a stroke. However, depending on the studies examined, its incidence ranges from 29% to over 80%.<sup>44,45</sup> Factors explaining this wide range include the severity of the stroke, its location and how it is diagnosed. OPD has also been shown to be common in various neurodegenerative diseases.<sup>3,46</sup> In Parkinson's disease, studies have showed that the majority of patients experience OPD. Some studies report a prevalence of dysphagia of up to 80% in this patient group.<sup>3,4,46,47</sup> Up to 100% of patients with patient with severe Amyotrophic Lateral Sclerosis (ALS) have OPD.<sup>48,49</sup>

In the general population, estimates of OPD also vary widely. In an Australian study examining the incidence of OPD, 1000 randomly selected individuals were sent questionnaires with which they were to assess subjective symptoms suggestive of dysphagia.<sup>1</sup> 16% of respondents stated they had suffered from at least one episode of OPD.<sup>2</sup> In a similar questionnaire based Swedish study of 556 individuals 20.9% of respondents reported globus like symptoms while 1.6% reported obstructive symptoms.<sup>3</sup>



**TABLE 2** Common causes of oropharyngeal dysphagia<sup>1-3,40-42</sup>

Common causes of oropharyngeal dysphagia	
Mechanical	Congenital
	Skeletal abnormalities
	Tumors of the head and neck
	Stenosis
	Foreign bodies
	Dental pathology
	Pathology affecting jaw movements
	Pharyngeal diverticula
	Xerostomia <sup>a</sup>
Infection	Infections causing oropharyngeal inflammation and ulceration
	Infections with neurological effects
Iatrogenic	Surgical aftereffects
	Medication
	Radiation to head and neck
Neurological	Reduced conscious level
	Dementia
	Cerebrovascular accidents (CVA)
	Diseases of the CNS
	Trauma
	CNS tumors
Neuromuscular	Aging
	Myasthenia Gravis
	Critical illness and sepsis
	Diseases of the muscles

It is important to note that while xerostomia can be a cause of dysphagia, it is rarely a cause in isolation. It instead often acts as a contributing cause to OPD.

OPD is recognized to be a common problem affecting elderly patients. Studies have shown that over 60% of elderly patients in nursing homes subjectively complain of OPD.<sup>5</sup>

## 6 | CAUSES OF DYSPHAGIA

When classifying the cause of OPD by underlying pathology, the disruptions affecting each stage of the swallowing process can be broadly grouped into mechanical, neurological, or neuromuscular problems. This can be seen in Table 2.<sup>2-4,44,50,51</sup>

### 6.1 | Mechanical

#### 6.1.1 | Congenital

Several congenital abnormalities which result in abnormalities of the oral cavity and pharynx can cause OPD. A common abnormality is

cleft lip and palate.<sup>52</sup> Individuals born with a cleft lip and palate often have difficulty swallowing normally due to their lack of a complete palate causing food and fluids to reflux into their nasal cavity when swallowing.<sup>53</sup> In addition the formation of a food bolus is impaired as the bolus is often shaped against the palate.<sup>8</sup> An enlarged tongue is termed macroglossia. This is usually a congenital condition which can cause dysphagia due to the largeness of the tongue in the oral cavity impairing bolus manipulation during the oral phase of swallowing.<sup>52</sup>

#### 6.1.2 | Pathology affecting the temporomandibular joint

Pathology affecting the temporomandibular joint directly affects the ability to masticate food thereby contributing to OPD. Dislocation of the temporomandibular joint can occur during excessive opening of the mouth when biting or yawning.<sup>12</sup> Dislocation can also occur following a blow to the side of the jaw.<sup>12</sup>

Osteoarthritis of the temporomandibular joint can cause severe pain when masticating.<sup>12</sup> This can impair the formation of a food bolus and cause OPD.

#### 6.1.3 | Teeth

Pathology affecting teeth can also affect the process of mastication. Potential pathology includes: missing teeth following trauma, iatrogenic input or infection or pain secondary to trauma or caries.<sup>12</sup>

#### 6.1.4 | Obstruction

Obstruction due to any cause in oral cavity or pharynx can impair the transport of a bolus. There are multiple iatrogenic and non-iatrogenic causes of obstruction. These include:

##### Stenosis

Stenosis of the pharynx is caused by variety of reasons. Scarring and subsequent pharyngeal narrowing can occur after: radiation to the head and neck or injury to the pharynx due to the ingestion of caustic or hot substances.<sup>32</sup> Dilatation of the stenosis or surgical reconstruction can overcome the obstruction.<sup>54</sup>

##### Tumors of the head and neck

Tumors affecting the head and neck have the potential of causing OPD.<sup>55</sup> This can occur in two distinct ways. Firstly the presence of a tumor can obstruct the oral cavity or pharynx and impair bolus formation or movement.<sup>56</sup> Tumors can also cause direct damage to the nerves of the oral cavity or pharynx. This in itself can impair oral bolus formation or initiation of the pharyngeal phase of swallowing.<sup>32</sup>

##### Foreign bodies

The ingestion of foreign bodies can cause obstruction of the oral cavity and pharynx. This can be resolved by the removal of the occluding object.<sup>32</sup>

### 6.1.5 | Pharyngeal diverticula

A pharyngeal diverticulum is a herniation of tissue between two muscles which form the inferior pharyngeal constrictors.<sup>12</sup> These are the thyropharyngeus and cricopharyngeus muscles.<sup>12,57,58</sup> The herniation occurs at a point of weakness between the two muscles caused Killian's Dehiscence. A diverticulum has the potential to retain food and fluids post swallow and can increase the risk of (postdeglutitive) aspiration.<sup>59</sup>

### 6.1.6 | Xerostomia

Individuals with an abnormally low volume of saliva are classified as having xerostomia.<sup>60</sup> Xerostomia impairs the oral phase of swallowing.<sup>61</sup> Importantly, while xerostomia often acts as a contributing factor to OPD, it rarely causes OPD in isolation. This difficulty has been shown to negatively impact patient's nutritional status. Furthermore, due to the loss of the antibacterial protection that saliva affords, patients with xerostomia are more at risk from aspiration pneumonia if aspiration occurs due to a higher oral bacterial load.<sup>5,61</sup> Causes of xerostomia include: systemic disease, postsurgical effects, radiation therapy, and medication.

#### Systemic disease

Several systemic diseases and clinical conditions can cause xerostomia. These range from dehydration to connective tissue diseases such as Sjogren's syndrome.<sup>62</sup>

### 6.1.7 | Infection

#### Oropharyngeal inflammation and ulceration

Infections with micro-organisms which cause mucosal inflammation or ulceration can be very painful. This can result in painful swallowing also known as odynophagia. Pain can impair the oral phase of swallowing. Examples of organisms which can cause oral mucosal inflammation, pharyngitis, or tonsillitis are: Herpes Simplex Virus, Cytomegalovirus, Epstein Barr Virus, Influenza, Human Immunodeficiency Virus, Streptococci, and Adenovirus.<sup>63</sup>

#### Neurological infections

Several infections can affect either the peripheral or central nervous systems and cause OPD. Examples of these infections include: botulism, syphilis, and diphtheria.<sup>32,64,65</sup>

## 6.2 | Iatrogenic

### 6.2.1 | Medication

#### Chemotherapeutic agents

The term mucositis is used to describe ulcerated or erythematous areas of mucosa which occur secondary to either chemotherapy or radiotherapy used for the treatment of cancer.<sup>66</sup> These areas of mucositis are often painful and if they occur in the oral cavity can

impair the oral phase of swallowing. In a 2003 study by Elting et al., 599 patient with myelosuppression secondary to chemotherapy were randomly selected and their notes retrospectively analyzed looking for mucositis.<sup>66</sup> There were 1236 cycles of chemotherapy in total within the study. 37% of these cycles resulted in mucositis. A 2007 study also by Elting et al. looked retrospectively at a group of 204 patients who had received radiotherapy for evidence of mucositis. 91% of these patients developed mucositis.<sup>67</sup>

#### Medication induced xerostomia

Anticholinergic medications are well known to cause xerostomia as a side effect.<sup>68</sup> However, several other classes of prescribed medication can also result in xerostomia. These include: antihistamines, tricyclic antidepressants, calcium channel blockers, angiotensin converting enzyme inhibitors, diuretics, and Parkinson's medications.<sup>68</sup> A recent study showed that up to 64% of patients with xerostomia take medications which have a side effect of xerostomia.<sup>60</sup>

#### Antipsychotics and medication induced Parkinsonism

OPD can occur in isolation with antipsychotic use or can occur as part of antipsychotic induced Parkinsonism.<sup>69</sup> Unfortunately no studies have been done investigating the prevalence of isolated OPD following antipsychotic use or OPD in medication induced Parkinsonism.

Antipsychotic medications act on dopaminergic neurons within the brain.<sup>70</sup> These neurons are an integral part of the extrapyramidal nervous system which regulates and orchestrates motor neurons supplying oral and pharyngeal muscles and coordinating their synchronous contraction.<sup>7</sup> As a result of this, antipsychotic medication predominately has an effect on the oropharyngeal phase of swallowing.<sup>71</sup> Multiple studies have shown that elderly patients are more at risk of extrapyramidal side effects including dysphagia than younger individuals.

Studies have shown the use of both typical and atypical antipsychotics such as haloperidol and risperidone cause OPD.<sup>72,73</sup> In addition antipsychotics have been shown to increase the risk of aspiration.<sup>74</sup> The table below details some of the common classes of medication with the potential to cause OPD (Table 3).<sup>42</sup>

#### Sedatives

Sedative medications have the potential to cause OPD.<sup>75</sup> This most commonly occurs due to a reduction in an individual's level of consciousness.<sup>76</sup> This impairs the initial voluntary phase of swallowing. Mastication, bolus formation, and lastly the adequate positioning of the bolus at the entrance to the pharynx are all negatively affected.<sup>44</sup>

Interestingly opiate medication has been shown to cause esophageal dysmotility.<sup>77</sup> This is thought to be caused by opiates binding to opiate receptors in the gastrointestinal tract.<sup>77</sup> This is analogous to their well-known constipating effect caused by a slowing of intestinal activity.<sup>77</sup> Despite their deleterious effect on esophageal motility, no studies have been done showing opiates cause pharyngeal dysmotility.



**TABLE 3** Common classes of medication with the potential to cause OPD<sup>42</sup>

Mechanism of action	Classes of medication	Examples
Xerostomia inducing medications	Antihistamines	Chlorpheniramine Loratadine Fexofenadine
	Anticholinergics	Atropine Ipratropium Oxybutynin
	Angiotensin converting enzyme inhibitors	Enalapril Lisinopril Captopril
	Tricyclic antidepressants	Amitriptyline Fluoxetine Sertraline
	Diuretics	Furosemide Spironolactone Bendroflumethiazide
Sedative medications	Opiates	Morphine Hydromorphone Oxycodone
	Benzodiazepines	Diazepam Lorazepam Midazolam
Neuromuscular medication	Muscle relaxants	Pancuronium Rocuronium Tubocurarine
Medications acting on the CNS	Atypical antipsychotics	Olanzapine Risperidone Quetiapine
	Typical antipsychotics	Haloperidol Chlorpromazine Prochlorperazine

## 6.2.2 | Surgery

Surgical or radiological treatments to the head and neck for example for tumors can themselves damage oral and pharyngeal structures and cause obstruction, xerostomia, or muscular incoordination.<sup>78,79</sup>

Xerostomia can be caused following head and neck surgery due to damage to or removal of salivary ducts, salivary glands, or the nerves supplying them.<sup>55,56</sup>

## 6.2.3 | Radiation

Radiotherapy to the head or neck can damage salivary glands and cause xerostomia.<sup>80</sup> Studies have shown that radiation induced salivary gland dysfunction is often irreversible and is due to apoptosis in exposed cells.<sup>81</sup> However, if the total radiation dose to the salivary glands is less than 25 Grays, there is potential for some recovery in saliva production.<sup>82</sup>

Stenosis can also be caused following radiotherapy to the head and neck administered to treat malignancy.<sup>83</sup>

## 6.3 | Neurological

### 6.3.1 | Cerebrovascular accidents

Cerebrovascular accidents (CVAs) also known as strokes are the most common cause of OPD of acute onset.<sup>49,84</sup> Unfortunately the majority of patients who have had strokes are unaware of their dysphagia and attempt to eat and drink as normal.<sup>84</sup> This has the potential for clinically adverse outcomes.

The location of the stroke can influence the type of dysphagia which is likely to occur. Strokes of the cerebral cortex can cause both oral and pharyngeal dysphagia.<sup>85</sup> However, their effect on the oral phase of swallowing is thought to be due to the resultant loss of cortical modulation of the oral swallow. This can cause problems ranging

from the inability to retain food within the mouth to incoordination of the tongue.<sup>85,86</sup> Conversely strokes of the brainstem can often cause disruption to the pharyngeal phase of swallowing due to the damage to: the NTS, the CPG, swallowing interneurons and or efferent motor neurons.<sup>85</sup>

Experiments utilizing the non-invasive technique of transcranial magnetic stimulation (TMS) to map neuronal connections from the motor cortex to identified target swallowing muscles have identified asymmetrical cortical representation of pharyngeal swallowing musculature.<sup>87</sup> This indicates that individuals have a dominant and non-dominant hemisphere with respect to swallowing.<sup>87</sup> Damage to the dominant cerebral hemisphere is more likely to result in OPD and carries a higher risk of aspiration. By contrast, recovery post unilateral stroke is thought to involve compensatory changes of the contralateral (undamaged) hemisphere.<sup>87</sup>

### Idiopathic Parkinson's disease

Idiopathic Parkinson's disease (PD) is a common, progressive disease of the central nervous systems, wherein there is a loss of dopaminergic neurons of the substantia nigra.<sup>88</sup> It is recognized by the presence of bradykinesia along with one or more of: Postural instability, rigidity, and a tremor.<sup>88</sup> Parkinsonism is the term used for the presence of these symptoms. Parkinsonism has long been known to cause OPD. Studies have shown that the presence of OPD in PD can be as high as 82%.<sup>47</sup>

Parkinsonism can cause OPD in various ways. These include:

- **Bradykinesia:** Bradykinesia is a key feature of Parkinsonism. It has been shown in various studies to cause a slowing of the unconscious pharyngeal reflex triggered when the masticated food bolus is pushed into the pharynx.<sup>88</sup> This increases the time it takes for the food bolus to transit the oropharynx thereby increasing the risk of aspiration.<sup>35</sup>
- **Dystonia:** Dystonia has been shown to cause impaired relaxation of the upper esophageal sphincter.<sup>88,89</sup> Studies have shown impaired upper esophageal relaxation to be associated with OPD.<sup>14</sup>
- **Dyskinesia:** Dyskinesia results in uncoordinated contraction of the muscles of the oropharynx.<sup>88</sup> This increases the amount of pharyngeal residue within the esophagus thereby increasing the risk of aspiration.<sup>84,89</sup>

### Motor neuron disease

Motor neuron disease (MND) is an idiopathic, degenerative condition causing significant morbidity and mortality.<sup>90</sup> Amyotrophic lateral sclerosis (ALS) is the most common form of MND.<sup>91</sup> It results in damage to upper and lower motor neurons in the CNS.<sup>49,90</sup> The hallmark of this disease is severe progressive muscle weakness.<sup>49</sup> Dysphagia related to upper motor neuron damage include jaw and tongue spasticity while lower motor neuron injury often leads to muscle atrophy.<sup>92</sup> Muscles of the oral cavity and pharynx are commonly affected leading to impaired bolus formation and transport.<sup>32</sup> When considering patients of both genders at all ages of presentation, 25% of patients

with ALS present with bulbar symptoms.<sup>93,94</sup> MND can affect both the oral and pharyngeal phase of swallowing.<sup>95,96</sup> However, most of the initial swallowing problems in patients with ALS affect the oral phase of swallowing.<sup>96</sup>

Progressive bulbar palsy MND is another subtype of MND. It occurs less commonly than ALS affecting 25% of individuals with MND. Affected individuals develop OPD early in the disease process.<sup>97</sup>

Kennedy disease is an X linked genetic form of MND caused by an expansion of a trinucleotide repeat sequence.<sup>98</sup> Pharyngeal dysfunction occurs in a similar fashion to ALS.<sup>93</sup> Magnetoencephalography (MEG) on patients with Kennedy disease demonstrated increased bilateral sensorimotor activity with greater activity noted over the right hemisphere.<sup>98</sup> Bilateral cortical activity is thought to be due to a degree of cortical swallowing specialization (or compensation) with the left hemisphere mostly influencing the oral phase of swallowing while the right hemisphere influences the pharyngeal phase.<sup>93</sup> The increased right sided activity was considered indicative of cortical compensation for pharyngeal dysphagia.<sup>93</sup>

### Other diseases causing CNS lesions

Several other infectious and non-infectious diseases can cause CNS damage and subsequent OPD via the mechanisms described above. These include: CNS tumors; trauma; encephalopathy (viral, bacterial or parasitic); tuberculosis affecting the CNS; and multiple sclerosis.<sup>49</sup>

### Reduced consciousness

Reduced consciousness can cause OPD.<sup>75,76</sup> This is because reduction in an individual's level of consciousness impairs the cortical modulation of the initial oral phase of swallowing.<sup>76</sup> It is interesting to note the findings of studies which show that in deep sleep there is a significant reduction in an individual's rate of swallowing.<sup>99</sup> This explains the increased amount of salivary leakage from the mouths of sleeping individuals.<sup>99</sup> However, if the SLN, CPG, interneurons, and motor nerves are unaffected, the pharyngeal swallow can be spared.<sup>7</sup> It is interesting to note that while the pharyngeal swallow may not be directly affected—depending on the cause of the reduced conscious level—rapid propulsion of food and fluids through the oropharynx relies on adequate propulsive force applied by the tongue. Without tongue propulsion it can be argued that bolus transit across the oropharynx would be prolonged therefore increasing the risk of aspiration.

### Dementia and delirium

Dementia and delirium both have the potential to cause OPD.<sup>46,100</sup> Delirium has the potential to cause OPD in two distinct ways. Firstly delirium can cause a reduction in conscious level thereby increasing the risk of OPD.<sup>101,102</sup> However, delirium can also impair the voluntary oral phase of swallowing through its negative effect on higher cortical functioning.<sup>5,102</sup> Different dementias tend to exert their malign effect on oropharyngeal swallowing through their neurodegenerative effect on higher cortical functioning.<sup>46,102,103</sup> However, Lewy body dementia also leads to Parkinson's like oropharyngeal muscle dysfunction.<sup>103</sup>

## 6.4 | Neuromuscular

### 6.4.1 | Myasthenia gravis

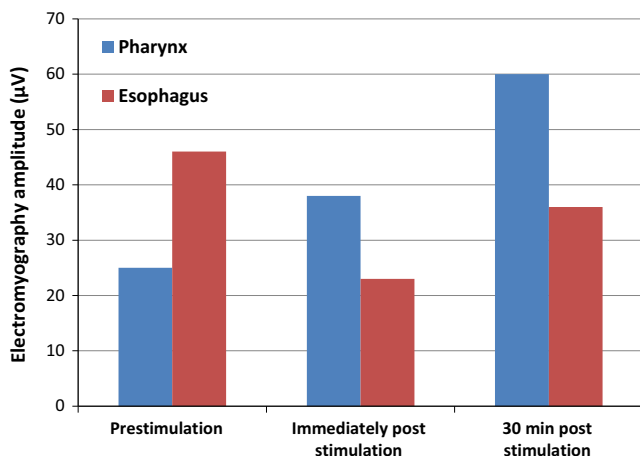
Myasthenia gravis (MG) is an autoimmune disease caused by autoantibodies which target nicotinic acetylcholine receptors on post synaptic membranes at neuromuscular junctions.<sup>84,104</sup> This causes muscle weakness. OPD can be caused by MG. It causes weakness and fatigability of the muscles of the oral cavity and pharynx.<sup>105</sup> Treatment involves the use of acetylcholinesterase inhibitors and immunosuppressant medication.<sup>106</sup>

### 6.4.2 | Other diseases of the muscles

Several intrinsic muscle diseases can affect the muscles of the mouth and oropharynx and cause OPD. These can be congenital or acquired. Diseases include: polymyositis, dermatomyositis, and muscular dystrophy.<sup>84,107</sup>

### 6.4.3 | Aging

The effects of aging result in changes to the oropharynx which affect the process of swallowing but are not pathological. This is termed presbyphagia.<sup>1,22</sup> Studies have shown a decrease in tongue muscle mass in elderly patients.<sup>108,109</sup> This is thought to reflect the well-known phenomenon of decreased skeletal muscle mass in the elderly, also known as sarcopenia. Studies have shown that as a result of decreased tongue muscle mass, lingual pressure generation declines with age.<sup>108,110</sup> In addition tongue pressures are generated over a longer period of time. The effect of this is to prolong the oral phase of swallowing.<sup>110</sup> Studies have also showed that the pharyngeal phase of swallowing is significantly prolonged in the elderly.<sup>1,5</sup> Specifically, there is a slowing of LV closure and UES relaxation compared to

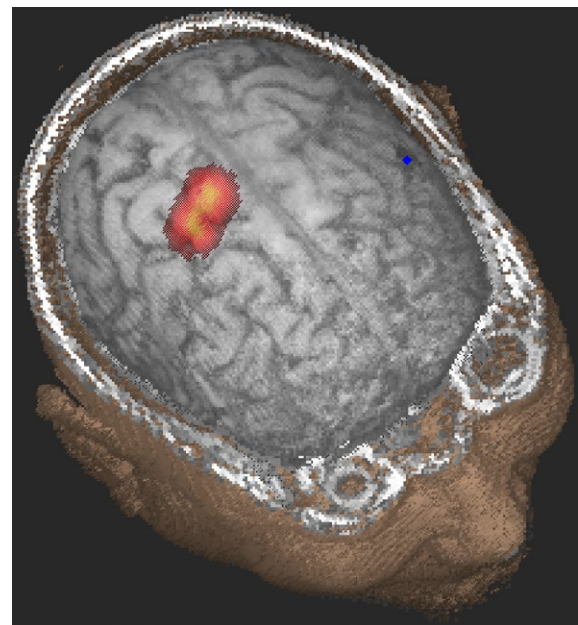


**FIGURE 2** Illustration depicting pharyngeal stimulation and its subsequent effects on EMG amplitude recordings from pharyngeal and esophageal muscles following TMS. Adapted from: Hamdy S. Long-term reorganization of human motor cortex driven by short-term sensory stimulation. *Nature Neuroscience* 1, 64-68 (1998)

younger individuals. This prolongation is thought to be partly due to age related neuronal loss in the brain and tissues causing impaired sensation, brain processing, and muscular coordination.<sup>111</sup> In addition, age-related sarcopenic changes have been described that affect the muscles of the oropharynx.<sup>5</sup> An example of this is a study which compared CT images of the geniohyoid muscle bulk of healthy elderly individuals (average age 78), with healthy young people (average age 32). The study showed a significant decrease in geniohyoid muscle bulk in the elderly group compared with the younger group.<sup>112</sup> Several studies have shown that the UES has a narrower opening diameter during swallowing in the elderly compared to the young. This is thought to be due to muscle weakness.<sup>113,114</sup> Studies have shown increased post swallow pharyngeal residue in elderly patients. The end result of all these changes is to reduce the functional swallowing reserve of the healthy older individual. Presbyphagia is thought to explain why the elderly are more at risk of dysphagia than their younger counterparts.<sup>1</sup> The overall slowing of the swallowing process and delay in LV closure leaves boluses in front of the unprotected airway for longer.<sup>5,21</sup> A recent study has shown that the prevalence of symptoms of dysphagia in healthy elderly individuals is 13%.<sup>115</sup>

### 6.4.4 | Critical illness and sepsis

Critical illness is a key cause of muscle atrophy. Several changes to normal physiology are found during critical illness which together can cause decreased muscle mass.<sup>116,117</sup> These changes include increased energy requirements on a background of decreased food intake;



**FIGURE 3** A surface rendering of the brain Magnetic Resonance Image (MRI) of a patient with dysphagia in the first week after stroke where the transcranial magnetic stimulation (TMS) activation data have been co-registered to the brain surface. The darkened area on the adjacent lower brain region marks the location of the stroke. The colored map represents the motor evoked responses in the pharynx, with yellow indicating large responses

inactivity, increased levels of inflammatory cytokines; neuronal loss, and the sepsis itself.<sup>118,119</sup> There are several neuromuscular changes that also take place due to sepsis in critical illness.<sup>120</sup>

Various catabolic stimuli including sepsis can cause muscle atrophy.<sup>121,122</sup> Atrophy related weakness occurs in two ways. There is degradation of the contractile myofibrillar apparatus which causes a reduction in strength. In addition degradation of mitochondria by autophagy causes decreased aerobic endurance.<sup>122</sup> The systemic inflammation caused by sepsis results in increased levels of inflammatory cytokines such as tumor necrosis factor alpha and interferon gamma.<sup>118,119,122</sup> This in combination with other atrophic factors such as sepsis mediated glucocorticoid release influences the activation of the ubiquitin proteasome system (UPS). The UPS breaks down myofibrils.

In addition to its wasting effect on musculature, sepsis has been identified as a cause of polyneuropathy in critically unwell individuals. This is thought to be due to inflammatory axonal injury caused as part of the systemic inflammatory response of sepsis.<sup>117,120,123</sup> These neuromuscular changes have been termed critical illness myopathy (CIM) and critical illness polyneuropathy (CIP).<sup>116,117</sup> Studies have shown that these two processes can exist in isolation but often occur together. Multiple studies have also identified a substantial risk of CIP and CIM in patients with sepsis on intensive care units (ICU). This risk can be up to 46%. However, there is unfortunately no current consensus on the diagnosis of critical illness neuromuscular abnormalities (CINMA).<sup>117</sup> Some experts advocate diagnosis based on clinical signs while others advocate the use of electrophysiological methods.<sup>120</sup>

## 7 | MECHANISMS OF NEUROGENIC DYSPHAGIA AND IT'S RECOVERY

In 1996 a study was conducted to establish the topographical cortical representation of the human esophagus.<sup>124</sup> Ten healthy volunteers were selected and TMS was used to stimulate 1 cm areas of the cortex. Both hemispheres were stimulated in turn. Esophageal response was measured 2 cm below the UES. It was found that esophageal responses were caused by stimulation of either the right or left cerebral hemisphere. The area of representation was thought to be in either the anterior motor or premotor cortices. In addition the area of greatest response was found to be asymmetrical being greater in the right hemisphere than the left in most subjects.<sup>124</sup> Later that year another study was published where TMS was used to study the cortical topographic representation of oral, pharyngeal and esophageal musculature in 20 healthy individuals.<sup>125</sup> In addition to this the topography of pharyngeal musculature was studied in two patients with stroke. Similar to the first study, it was found that the cortical representation of swallowing musculature was located in the premotor or motor cortices, was discreet and bilateral but showed some asymmetry. Interestingly in the dysphagic stroke patient studied the pharyngeal cortical area was noted to have reduced in size.<sup>125</sup>

In a study published in 1997 positron emission tomography (PET) was used to identify the regions within the brain that are responsible for painful and non-painful esophageal stimulation in humans. Eight

healthy individuals were selected and an inflatable balloon used to induce either non painful sensation or painful sensation.<sup>126</sup> PET was performed for each sensation. Magnetic resonance imaging brain scans were also performed for each individual and used to confirm the locations identified by PET. Non painful sensation was found to bilaterally activate the operculum, primary somatosensory cortex, and insula. Painful sensation affected the aforementioned regions and the anterior cingulate gyrus and right anterior insular cortex.<sup>126</sup>

In 1998 a follow-on study was published showing how pharyngeal stimulation of eight healthy individuals causes increased excitability of the motor cortex and an increase in the cortical area of pharyngeal representation.<sup>127</sup> This effect lasted for at least 30 minutes after cessation of the stimulus (Figure 2). This study suggested that pharyngeal stimulation was a potential method for encouraging recovery of function in dysphagic patients (Figure 3).<sup>127</sup> One of the key findings of this and a follow-up study was sensory stimulation at certain parameters, can lead to increased activation of brain regions important to swallowing in health and dysphagic individuals with strokes. In dysphagic stroke patients, cortical activity was seen to be enhanced, mostly in the undamaged hemisphere. The result of this was an improvement in swallowing.<sup>127,128</sup> Interestingly a similar increase in excitation of motor cortices could also be induced by direct hemispheric TMS.<sup>129</sup> Moreover, two later studies showed that the use of TMS to precondition the cerebellum could modulate the cortical pharyngeal response.<sup>130,131</sup> This highlighted a role for TMS of the cerebellum being useful in promoting the recovery of dysphagia caused by neurological damage. In addition, 1-Hz repetitive TMS was shown to be able to create a virtual lesion in oropharyngeal cortical sites in healthy individuals.<sup>132</sup> The modification in swallowing caused by this process was shown to be similar to the changes in swallowing physiology caused by strokes.<sup>132</sup> These studies and others have laid the platform for a new era of neuromodulation to treat OPD in neurological conditions, and future trials of these approaches are awaited.

## 8 | CONCLUSION

Swallowing is a multidimensional complex process requiring the interaction and integration of conscious and semi-automatic systems along with the precise co-ordination of various muscle groups in the oral cavity and pharynx. Damage to any part of the process can result in decompensation and subsequent dysphagia. Decompensation can potentially be disastrous and if not promptly addressed can result in malnutrition, dehydration and aspiration.

## DISCLOSURES

None.

## REFERENCES

1. Ney D, Weiss J, Kind A, Robbins J. Senescent swallowing: impact, strategies and interventions. *Nutr Clin Pract*. 2009;24:395-413.

2. Eslick G, Talley J. Dysphagia: epidemiology, risk factors and impact on quality of life - a population-based study. *Aliment Pharmacol Ther.* 2008;27:971-979.
3. Kuhlemeier K. Epidemiology and dysphagia. *Dysphagia.* 1994;9:209-217.
4. Malagelada J, Bazzoli F, Elewaut A, et al. World gastroenterology organisation practice guidelines: world gastroenterology organisation. *Dysphagia.* 2007. Available at <http://www.worldgastroenterology.org/guidelines/global-guidelines/dysphagia/dysphagia-english>. Accessed June 20, 2016.
5. Rofes L, Arreola V, Almirall J, et al. Diagnosis and management of oropharyngeal dysphagia and its nutritional and respiratory complications in the elderly. *Gastroenterol Res Pract.* 2011;2011:13.
6. Jaradeh S. Neurophysiology of swallowing in the aged. *Dysphagia.* 1994;9:218-220.
7. Jean A. Brain stem control of swallowing: neuronal network and cellular mechanisms. *Physiol Rev.* 2001;31:929-969.
8. Matsuo K, Palmer J. Anatomy and physiology of feeding and swallowing - normal and abnormal. *Phys Med Rehabil Clin N Am.* 2008;19:691-707.
9. Cook I, Kahrilas P. AGA technical review on management of oropharyngeal dysphagia. *Gastroenterology.* 1999;116:455-478.
10. Pedersen AM, Bardow A, Jensen SB, Nauntofte B. Saliva and gastrointestinal functions of taste, mastication, swallowing and digestion. *Oral Dis.* 2002;8:117-129.
11. Kupirovič UP, Elmadfa I, Juillerat MA, Raspor P. Effect of saliva on physical food properties in fat texture perception. *Crit Rev Food Sci Nutr.* 2016;57:1061-1077.
12. Moore K, Dalley A. *Clinically Oriented Anatomy*, 5th edn. United States of America: Lippincott Williams and Wilkins; 2006.
13. Kier W. Tongues, tentacles and trunks: the biomechanics of movement in muscular-hydrostats. *Zool J Linn Soc.* 1985;83:307-324.
14. Cook I. Clinical disorders of the upper esophageal sphincter. *GI Motility Online.* 2006. Available at <http://www.nature.com/gimo/contents/pt1/full/gimo19.html#relatedcontent>. Accessed June 20, 2016.
15. Asoh R, Goyal RK. Manometry and electromyography of the upper esophageal sphincter in the opossum. *Gastroenterology.* 1978;74:514-520.
16. Lang IM, Dantas RO, Cook IJ, Dodds WJ. Videoradiographic, manometric, and electromyographic analysis of canine upper esophageal sphincter. *Am J Physiol.* 1991;260:G911-G919.
17. Perlman A. Electromyography in oral and pharyngeal motor disorders. *GI Motility online.* 2006. Available at <http://www.nature.com/gimo/contents/pt1/full/gimo32.html>. Accessed June 20, 2016.
18. Dantas RO, Kern MK, Massey BT, et al. Effect of swallowed bolus variables on oral and pharyngeal phases of swallowing. *Am J Physiol.* 1990;258(5 Pt 1):G675-G681.
19. Bisch EM, Logemann JA, Rademaker AW, Kahrilas PJ, Lazarus CL. Pharyngeal effects of bolus volume, viscosity, and temperature in patients with dysphagia resulting from neurologic impairment and in normal subjects. *J Speech Hear Res.* 1994;37:1041-1059.
20. Choi KH, Ryu JS, Kim MY, Kang JY, Yoo SD. Kinematic analysis of dysphagia: significant parameters of aspiration related to bolus viscosity. *Dysphagia.* 2011;26:392-398.
21. Kahrilas P, Lin S, Rademaker A, Logemann J. Impaired deglutitive airway protection: a videofluoroscopic analysis of severity and mechanism. *Gastroenterology.* 1997;113:1457-1464.
22. Goyal RK, Mashimo H. Physiology of oral, pharyngeal, and esophageal motility. *GI Motility online.* 2006. Available at <http://www.nature.com/gimo/contents/pt1/full/gimo1.html>. Accessed June 21, 2016.
23. Jean A. Brain stem control of swallowing: neuronal networks and cellular mechanisms. *Physiol Rev.* 2001;81:929-969.
24. Monfared A, Kim D, Jaikumar S, Gorti G, Kam A. Microsurgical anatomy of the superior and recurrent laryngeal nerves. *Neurosurgery.* 2001;49:925-932; discussion 32-3.
25. Miller AJ. Characteristics of the swallowing reflex induced by peripheral nerve and brain stem stimulation. *Exp Neurol.* 1972;34:210-222.
26. Kessler JP, Jean A. Identification of the medullary swallowing regions in the rat. *Exp Brain Res.* 1985;57:256-263.
27. Kessler JP, Cherkaoui N, Catalin D, Jean A. Swallowing responses induced by microinjection of glutamate and glutamate agonists into the nucleus tractus solitarius of ketamine-anesthetized rats. *Exp Brain Res.* 1990;83:151-158.
28. Kessler JP, Jean A. Evidence that activation of N-methyl-D-aspartate (NMDA) and non-NMDA receptors in the nucleus tractus solitarii trigger swallowing. *Eur J Pharmacol.* 1991;201:59-67.
29. Jean A, Kessler JP, Tell F. *Nucleus of the solitary tract*. Boca Raton: CRC Press; 1994:p. 355-69.
30. Hamdy S, Rothwell J, Brooks D, Bailey D, Aziz Q, Thompson D. Identification of the cerebral loci processing human swallowing with H<sub>2</sub><sup>15</sup>O PET activation. *J Neurophysiol.* 1999;81:1917-1926.
31. Amano O, Mizobe K, Bando Y, Sakiyama K. Anatomy and histology of rodent and human major salivary glands: -overview of the Japan salivary gland society-sponsored workshop-. *Acta Histochem Cytochem.* 2012;45:241-250.
32. McCulloch T, Jaffe D. Head and neck disorders affecting swallowing. *GI Motility Online.* 2006. Available at <http://www.nature.com/gimo/contents/pt1/full/gimo1.html>. Accessed June 22, 2016.
33. Dodds WJ, Taylor AJ, Stewart ET, Kern MK, Logemann JA, Cook IJ. Tipper and dipper types of oral swallows. *AJR Am J Roentgenol.* 1989;153:1197-1199.
34. Hiieamae KM, Palmer JB. Food transport and bolus formation during complete feeding sequences on foods of different initial consistency. *Dysphagia.* 1999;14:31-42.
35. Kendall KA, McKenzie S, Leonard RJ, Gonçalves MI, Walker A. Timing of events in normal swallowing: a videofluoroscopic study. *Dysphagia.* 2000;15:74-83.
36. Pearson WG, Molfenter SM, Smith ZM, Steele CM. Image-based measurement of post-swallow residue: the normalized residue ratio scale. *Dysphagia.* 2013;28:167-177.
37. Molfenter SM, Steele CM. The relationship between residue and aspiration on the subsequent swallow: an application of the normalized residue ratio scale. *Dysphagia.* 2013;28:494-500.
38. Cook IJ, Dodds WJ, Dantas RO. Opening mechanisms of the human upper esophageal sphincter. *Am J Physiol.* 1989;257:G748-G759.
39. Williams RB, Wallace KL, Ali GN, Cook IJ. Biomechanics of failed deglutitive upper esophageal sphincter (UES) relaxation in patients with neurogenic dysphagia. *Am J Physiol.* 2002;283:G16-G26.
40. Hukuhara T, Okada H. Effects of deglutition upon the spike discharges of neurones in the respiratory center. *Jpn J Physiol.* 1956;6:162-166.
41. Sumi T. The activity of brain-stem respiratory neurons and spinal respiratory motoneurons during swallowing. *J Neurophysiol.* 1963;26:466-477.
42. Kobayashi S, Kubo H, Yanai M. Impairment of the swallowing reflex in exacerbations of COPD. *Thorax.* 2007;62:1017.
43. Cvejic L, Harding R, Churchward T, et al. Laryngeal penetration and aspiration in individuals with stable COPD. *Respirology.* 2011;16:269-275.
44. Falsetti P, Acciai C, Palilla R, et al. Oropharyngeal dysphagia after stroke: incidence, diagnosis, and clinical predictors in patients admitted to a neurorehabilitation unit. *J Stroke Cerebrovasc Dis.* 2009;18:329-335.
45. Martino R, Foley N, Bhogal S, Diamant N, Speechley M, Teasell R. Dysphagia after stroke. *Stroke* 2005;36:2756-2763.
46. Easterling CS, Robbins E. Dementia and dysphagia. *GeriatrNurs.* 2008;29:275-285.
47. Kalf JG, de Swart BJ, Bloem BR, Munneke M. Prevalence of oropharyngeal dysphagia in Parkinson's disease: a meta-analysis. *Parkinsonism Relat Disord* 2012;18: p.311-315.



48. Ruoppolo G, Schettino I, Frasca V, et al. Dysphagia in amyotrophic lateral sclerosis: prevalence and clinical findings. *Acta Neurol Scand*. 2013;128:397-401.
49. Daniels SK. Neurological disorders affecting oral, pharyngeal swallowing. *GI Motility online*. 2006. Available at <http://www.nature.com/gimo/contents/pt1/full/gimo34.html>. Accessed June 21, 2016.
50. Gordon C, Hewer RL, Wade DT. Dysphagia in acute stroke. *BMJ*. 1987;295:411-414.
51. Balzer KM. Drug-Induced Dysphagia: International Journal of MS Care. 2015 <http://ijmsc.org/doi/pdf/10.7224/1537-2073-2.1.40>. Accessed July 10, 2016.
52. Tanaka SA, Mahabir RC, Jupiter DC, Menezes JM. Updating the epidemiology of cleft lip with or without cleft palate. *Plast Reconstr Surg*. 2012;129:511e-518e.
53. Bardach J, Salyer KE. Surgical Techniques in Cleft Lip and Palate. 1991. p. 224-73.
54. Wisdom G, Blitzer A. Surgical therapy for swallowing disorders. *Otolaryngol Clin North Am*. 1998;31:537-560.
55. Grobbelaar EJ. Nutritional challenges in head and neck cancer. *Clin Otolaryngol Allied Sci*. 2004;29:307-313.
56. Watt E, Whyte F. The experience of dysphagia and its effect on the quality of life of patients with oesophageal cancer. *Eur J Cancer Care (Engl)*. 2003;12:183-193.
57. Cook IJ, Blumbergs P, Cash K, Jamieson GG, Shearman DJ. Structural abnormalities of the cricopharyngeus muscle in patients with pharyngeal (Zenker's) diverticulum. *J Gastroenterol Hepatol*. 1992;7:556-562.
58. Schulze SL, Rhee JS, Kulpa JI, Danielson SK, Toohill RJ, Jaradeh SS. Morphology of the cricopharyngeal muscle in Zenker and control specimens. *Ann Otol Rhinol Laryngol*. 2002;111(7 Pt 1):573-578.
59. Skinner DB, Altorki N, Ferguson M, Little G. Zenker's diverticulum: clinical features and surgical management. *Dis Esoph*. 1988;1:19-22.
60. Guggenheimer J, Moore PA. Xerostomia: etiology, recognition and treatment. *J Am Dent Assoc*. 2003;134:61-69; quiz 118-9.
61. Scully C, Felix DH. Oral medicine – update for the dental practitioner: dry mouth and disorders of salivation. *Br Dent J*. 2005;199:423-427.
62. Caruso ea. Objective measures of swallowing in patients with primary Sjogren's syndrome. *Dysphagia* 1998;4:101-105.
63. Alcaide ML, Bisno AL. Pharyngitis and epiglottitis. *Infect Dis Clin North Am* 2007;21:449-469, vii.
64. Vargas AP, Carod-Artal FJ, Del Negro MC, Rodrigues MP. Dementia caused by neurosyphilis: clinical and neuropsychological follow-up of a patient. *Arq Neuropsiquiatr*. 2000;58(2B):578-582.
65. Mangilli LD, Andrade CR. Botulism and dysphagia. *Pro Fono*. 2007;19:215-222.
66. Elting LS, Cooksley C, Chambers M, Cantor SB, Manzullo E, Rubenstein EB. The burdens of cancer therapy. Clinical and economic outcomes of chemotherapy-induced mucositis. *Cancer*. 2003;98:1531-1539.
67. Elting LS, Cooksley CD, Chambers MS, Garden AS. Risk, outcomes, and costs of radiation-induced oral mucositis among patients with head-and-neck malignancies. *Int J Radiat Oncol Biol Phys*. 2007;68:1110-1120.
68. Bostock C, McDonald C. Antimuscarinics in older people: dry mouth and beyond. *Dental Update*. 2016;43:186-188.
69. Rudolph JL, Gardner KF, Gramigna GD, McGlinchey RE. Antipsychotics and oropharyngeal dysphagia in hospitalized older patients. *J Clin Psychopharmacol*. 2008;28:532-535.
70. Dziejewski R, Warnecke T, Schnabel M, et al. Neuroleptic-induced dysphagia: case report and literature review. *Dysphagia*. 2007;22:63-67.
71. Leopold NA. Dysphagia in drug-induced parkinsonism: a case report. *Dysphagia*. 1996;11:151-153.
72. Stewart JT. Dysphagia associated with risperidone therapy. *Dysphagia*. 2003;18:274-275.
73. Shin HW, Chung SJ. Drug-induced parkinsonism. *J Clin Neurol*. 2012;8:15-21.
74. Trifirò G. Antipsychotic drug use and community-acquired pneumonia. *Curr Infect Dis Rep*. 2011;13:262-268.
75. Karkos PD, Papouliakos S, Karkos CD, Theochari EG. Current evaluation of the dysphagic patient. *Hippokratia*. 2009;13:141-146.
76. Morgan A, Ward E, Murdoch B, Kennedy B, Murison R. Incidence, characteristics, and predictive factors for Dysphagia after pediatric traumatic brain injury. *J Head Trauma Rehabil*. 2003;18:239-251.
77. Kraichley R, Arora A, Murray J. Opiate-induced oesophageal dysmotility. *Aliment Pharmacol Ther*. 2010;31:601-606.
78. Hirano M. Dysphagia following various degrees of surgical resection for oral cancer. *Ann Otol Rhinol Laryngol*. 1992;101:138-141.
79. McConnel FS. Surgical variables affecting postoperative swallowing efficiency in oral cancer patients: a pilot study. *Laryngoscope*. 1994;104:87-90.
80. Tiwana MS, Mahajan MK, Uppal B, et al. Whole saliva physico-biochemical changes and quality of life in head and neck cancer patients following conventional radiation therapy: a prospective longitudinal study. *Indian J Cancer*. 2011;48:289-295.
81. Van Luijk P, Pringle S, Deasy JO, et al. Sparing the region of the salivary gland containing stem cells preserves saliva production after radiotherapy for head and neck cancer. *Sci Transl Med*. 2015;7:305ra147.
82. Braam PM, Terhaard CH, Roesink JM, Raaijmakers CP. Intensity-modulated radiotherapy significantly reduces xerostomia compared with conventional radiotherapy. *Int J Radiat Oncol Biol Phys*. 2006;66:975-980.
83. Tedla M, Valach M, Carrau RL, et al. Impact of radiotherapy on laryngeal intrinsic muscles. *Eur Arch Otorhinolaryngol*. 2012;269:953-958.
84. Massey B, Shaker R. Oral, pharyngeal and upper esophageal sphincter motility disorders. *GI Motility Online*. 2006. Available at <http://www.nature.com/gimo/contents/pt1/full/gimo19.html>. Accessed June 21, 2016.
85. Han DS, Chang YC, Lu CH, Wang TG. Comparison of disordered swallowing patterns in patients with recurrent cortical/subcortical stroke and first-time brainstem stroke. *J Rehabil Med*. 2005;37:189-191.
86. Smithard D. The natural history of dysphagia following a stroke. *Dysphagia*. 1997;12:188-193.
87. Singh S, Hamdy S. Dysphagia in stroke patients. *Postgrad Med J*. 2006;82:383-391.
88. Ali GN, Wallace KL, Schwartz R, de Carle DJ, Zagami A, Cook IJ. Mechanisms of oral-pharyngeal dysphagia in patients with Parkinson's disease. *Gastroenterology*. 1996;110:383-392.
89. Chaumartin N, Monville M, Lachaux B. Dysphagia or dysphagias during neuroleptic medication?. *Encephale*. 2012;38:351-355.
90. Haverkamp LJ, Appel V, Appel SH. Natural history of amyotrophic lateral sclerosis in a database population. Validation of a scoring system and a model for survival prediction. *Brain*. 1995;118(Pt 3):707-719.
91. Chiò A, Logroscino G, Traynor BJ, et al. Global epidemiology of amyotrophic lateral sclerosis: a systematic review of the published literature. *Neuroepidemiology*. 2013;41:118-130.
92. Teismann I, Warnecke T, Suntrup Sea. Cortical processing of swallowing in ALS patients with progressive dysphagia – a magnetoencephalographic study. *PLOS*. 2011;6:e19987.
93. Teismann IK, Warnecke T, Suntrup S, et al. Cortical processing of swallowing in ALS patients with progressive dysphagia—a magnetoencephalographic study. *PLoS ONE*. 2011;6:e19987.
94. Alonso A, Logroscino G, Jick SS, Hernán MA. Incidence and lifetime risk of motor neuron disease in the United Kingdom: a population-based study. *Eur J Neurol*. 2009;16:745-751.
95. Solazzo A, Monaco L, Vecchio LD, et al. Earliest videofluorometric pharyngeal signs of dysphagia in ALS patients. *Dysphagia*. 2014;29:539-544.



96. Ertekin C, Aydogdu I, Yüceyar N, Kiylioglu N, Tarlaci S, Uludag B. Pathophysiological mechanisms of oropharyngeal dysphagia in amyotrophic lateral sclerosis. *Brain*. 2000;123(Pt 1):125-140.
97. Swash M, Desai J. Motor neuron disease: classification and nomenclature. *Amyotroph Lateral Scler Other Motor Neuron Disord*. 2000;1:105-112.
98. Warnecke T, Oelenberg S, Teismann I, et al. Dysphagia in X-linked bulbospinal muscular atrophy (Kennedy disease). *Neuromuscul Disord*. 2009;19:704-708.
99. Sato K, Umeno H, Chitose S, Nakashima T. Deglutition and respiratory patterns during sleep in younger adults. *Acta Otolaryngol*. 2011;131:190-196.
100. Love AL, Cornwell PL, Whitehouse SL. Oropharyngeal dysphagia in an elderly post-operative hip fracture population: a prospective cohort study. *Age Ageing*. 2013;42:782-785.
101. Fong TG, Tulebaev SR, Inouye SK. Delirium in elderly adults: diagnosis, prevention and treatment. *Nat Rev Neurol*. 2009;5:210-220.
102. Sasegbon A, O'Shea L, Dark P, Hamdy S. Association between acute sepsis and oropharyngeal dysphagia in a hospitalised elderly population. 2016.
103. Alagiakrishnan K, Bhanji RA, Kurian M. Evaluation and management of oropharyngeal dysphagia in different types of dementia: a systematic review. *Arch Gerontol Geriatr*. 2013;56:1-9.
104. Willig TN, Paulus J, Lacau Saint Guily J, Béon C, Navarro J. Swallowing problems in neuromuscular disorders. *Arch Phys Med Rehabil*. 1994;75:1175-1181.
105. Ertekin C, Yüceyar N, Aydogdu I. Clinical and electrophysiological evaluation of dysphagia in myasthenia gravis. *J Neurol Neurosurg Psychiatry*. 1998;65:848-856.
106. Sieb JP. Myasthenia gravis: emerging new therapy options. *Curr Opin Pharmacol*. 2005;5:303-307.
107. Ertekin C. Oropharyngeal dysphagia in polymyositis/dermatomyositis. *Clin Neurol Neurosurg*. 2004;107:32-37.
108. Robbins J, Levine R, Wood J, Roecker EB, Lushei E. Age effects on lingual pressure generation as a risk factor for dysphagia. *J Gerontol*. 1995;50A:M257-M262.
109. Tamura F, Kikutani T, Tohara T, Yoshida M, Yaegaki K. Tongue thickness relates to nutritional status in the elderly. *Dysphagia*. 2012;27:556-561.
110. Nicosia M, Hind J, Roecker E, et al. Age effects on the temporal evolution of isometric and swallowing pressure. *J Gerontol*. 2000;55A:634-640.
111. Dan R, Kenshalo S. Somesthetic sensitivity in young and elderly humans. *J Gerontol*. 1986;41:732-742.
112. Feng X, Todd T, Lintzenich CR, et al. Aging-related geniohyoid muscle atrophy is related to aspiration status in healthy older adults. *J Gerontol A Biol Sci Med Sci*. 2013;68:853-860.
113. Shaw DW, Cook IJ, Gabb M, et al. Influence of normal aging on oral-pharyngeal and upper esophageal sphincter function during swallowing. *Am J Physiol*. 1995;268(3 Pt 1):G389-G396.
114. Shaker R, Kern m, Bardan E, et al. Augmentation of deglutitive upper esophageal sphincter opening in the elderly by exercise. *Am J Physiol*. 1997;1(6 Part 1):1518-1522.
115. Holland G, Jayasekaran V, Pendleton N, Horan M, Jones M, Hamdy S. Prevalence and symptom profiling of oropharyngeal dysphagia in a community dwelling of an elderly population: a self-reporting questionnaire survey. *Dis Esophagus*. 2011;24:476-480.
116. Desai S, Law T, Needham D. Long-term complications of critical care. *Crit Care Med*. 2011;39:371-379.
117. Stevens RD, Marshall SA, Cornblath DR, et al. A framework for diagnosing and classifying intensive care unit-acquired weakness. *Crit Care Med*. 2009;37:S299-S308.
118. Jeejeebhoy KN. Malnutrition, fatigue, frailty, vulnerability, sarcopenia and cachexia: overlap of clinical features. *Curr Opin Clin Nutr Metab Care*. 2012;15:213-219.
119. Bezerra A, Anderlini A, de Andrade F, Figueiroa J, Lemos A. Inspiratory muscle training and physical training for reducing neuromuscular dysfunction in critically ill adults in intensive care units (Protocol). *Cochrane Libr*. 2012. <https://doi.org/10.1002/14651858.CD009970>.
120. Stevens R, Dowdy D, Michaels R, Mendez-Tellez P, Pronovost P, Needham D. Neuromuscular dysfunction acquired in critical illness: a systematic review. *Intensive Care Med*. 2007;33:1876-1891.
121. Chioloro R, Revelly J-P, Tappy L. Energy metabolism in sepsis and injury. *Nutrition*. 1997;13:455-515.
122. Cohen S, Nathan JA, Goldberg AL. Muscle wasting in disease: molecular mechanisms and promising therapies. *Nature*. 2015;14:58-74.
123. Hocker SE, Wijidicks EFM. Neurologic Complications of Sepsis. *Continuum*. 2014;20:598-613.
124. Aziz Q, Rothwell J, Hamdy S, Barlow J, Thompson D. The topographic representation of esophageal motor function on the human cerebral cortex. *Gastroenterology*. 1996;111:855-862.
125. Hamdy S, Aziz Q, Rothwell JC, et al. The cortical topography of human swallowing musculature in health and disease. *Nat Med*. 1996;2:1217-1224.
126. Aziz Q, Andersson JL, Valind S, et al. Identification of human brain loci processing esophageal sensation using positron emission tomography. *Gastroenterology*. 1997;113:50-59.
127. Hamdy S, Rothwell JC, Aziz Q, Singh KD, Thompson DG. Long-term reorganization of human motor cortex driven by short-term sensory stimulation. *Nat Neurosci*. 1998;1:64-68.
128. Hamdy S, Aziz Q, Rothwell JC, et al. Recovery of swallowing after dysphagic stroke relates to functional reorganization in the intact motor cortex. *Gastroenterology*. 1998;115:1104-1112.
129. Gow D, Rothwell J, Hobson A, Thompson D, Hamdy S. Induction of long-term plasticity in human swallowing motor cortex following repetitive cortical stimulation. *Clin Neurophysiol*. 2004;115:1044-1051.
130. Vasant DH, Michou E, Mistry S, Rothwell JC, Hamdy S. High-frequency focal repetitive cerebellar stimulation induces prolonged increases in human pharyngeal motor cortex excitability. *J Physiol*. 2015;593:4963-4977.
131. Jayasekaran V, Rothwell J, Hamdy S. Non-invasive magnetic stimulation of the human cerebellum facilitates cortico-bulbar projections in the swallowing motor system. *Neurogastroenterol Motil*. 2011;23:831-e341.
132. Verin E, Michou E, Leroi AM, Hamdy S, Marie JP. "Virtual" lesioning of the human oropharyngeal motor cortex: a videofluoroscopic study. *Arch Phys Med Rehabil*. 2012;93:1987-1990.

**How to cite this article:** Sasegbon A, Hamdy S. The anatomy and physiology of normal and abnormal swallowing in oropharyngeal dysphagia. *Neurogastroenterol Motil*. 2017;00:e13100. <https://doi.org/10.1111/nmo.13100>